

ACP MESSENGER

Winter 2017



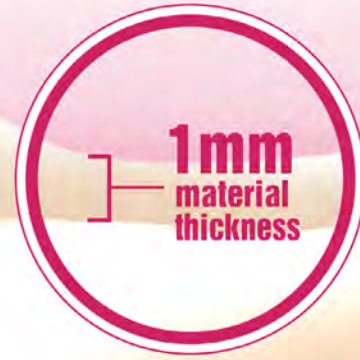Treating the exacting patient
Blending digital dentistry
and implant prosthodontics
Advanced digital
dental technologies

ACP
AMERICAN COLLEGE OF
PROSTHODONTISTS

Your smile.
Our specialty.®

IPS e.max[®]

500 MPa



High Strength, High Esthetics

Since its introduction, IPS e.max Lithium Disilicate has been relied upon for its high strength and high esthetics by the world's leading clinicians. Now, after 10 years of continuous quality testing, IPS e.max has demonstrated an average biaxial flexural strength of 500MPa*. With this proven record of strength, Ivoclar Vivadent now recommends **1mm** of material thickness** for minimally invasive restorations when adhesively bonded.

The IPS e.max you know, but better!

- **Minimally invasive preparation**
- **New translucency options**
- **500 MPa for maximum confidence**

For your next case choose the most trusted, most prescribed all ceramic in the world, make it e.max...because better matters.

**e.max is
even better!**

ivoclarvivadent.com

** 1mm material thickness suitable with adhesive cementation only.
* Ivoclar Vivadent data on file.

For more information, call us at 1-800-533-6825 in the U.S., 1-800-263-8182 in Canada.
© 2016 Ivoclar Vivadent, Inc. Ivoclar Vivadent and IPS e.max are registered trademarks of Ivoclar Vivadent, Inc.

ivoclar
vivadent[®]
passion vision innovation



With my friend Lorelai, everything has to be perfect. I love her, but she drives me crazy sometimes. This is a woman who can tell you the average snowfall by month at every ski resort in Colorado, off the top of her head. So when she said she wanted to improve her smile, I told her she had to see a prosthodontist. Nobody else could handle her! For advanced skills, treatment planning, and attention to detail, Lorelai met her match – and she’s glad she did.

In Every Issue

- 6 From the Editor: Best of both worlds

- 8 Case Presentation: Treating the exacting patient

- 12 At the Chair: Blending digital dentistry and implant prosthodontics

- 16 In the Office: Advanced digital dental technologies

- 27 Our Community

- 32 Classified Ads

Featured

- 18 **Leading the Industry:** Powerful CAD tools without complexity – NobelDesign™

- 20 **From the ACP Leadership:** Goals

- 22 **Annual Session News:** Tomorrow’s solutions in San Diego

Editor-in-Chief

Mathew T. Kattadiyil, DDS, MDS, MS, FACP

Associate Editors

Robert M. Taft, DDS, FACP
Nadim Z. Baba, DMD, MSD, FACP

Editor Emeritus

Lyndon F. Cooper, DDS, PhD, FACP

ACP Board of Directors

Susan E. Brackett, DDS, MS, FACP, President
Robert M. Taft, DDS, FACP, President-Elect
Nadim Z. Baba, DMD, MSD, FACP, Vice President
Carol A. Lefebvre, DDS, MS, FACP, Secretary
Mark C. Hutten, DDS, MS, FACP, Treasurer
Carl F. Driscoll, DMD, FACP, Immediate Past President
Cynthia M. Aita-Holmes, DMD, FACP, Regional Membership Director – Federal Services
John D. Ball, DDS, FACP, Regional Membership Director – Central
Douglas G. Benting, DDS, MS, FACP, Director, Prosthodontic Forum
Lars Bauma, DDS, MS, FACP, Director, Continuing & Professional Education Division
Linda Caradine-Poinsett, MBA, MJ, PhD, Executive Director
Lyndon F. Cooper, DDS, PhD, FACP, Chair, ACP Education Foundation
Betsy K. Davis, DMD, MS, Director, Maxillofacial Prosthetics Division
David A. Felton, DDS, MSD, FACP, Editor-in-Chief, *Journal of Prosthodontics*
Steven M. Morgano, DMD, FACP, Regional Membership Director – Northeast
Caroline T. Nguyen, DMD, MS, FACP, Regional Membership Director – International
B. Todd Pickle, DDS, MSD, FACP, Regional Membership Director – Rockies/Plains
Paivi A. Samant, DDS, Regional Membership Director – Eastern
Robert E. Stover, DDS, MS, FACP, Regional Membership Director – Pacific
Victoria A. Vickers, DDS, Director, Public Relations & Communications Division
Stephen A. Wagner, DDS, FACP, Director, Prosthodontic Practice & Patient Care Division
Alvin G. Wee, DDS, MS, MPH, PhD, Director, Education & Research Division

ACP Central Office Staff

Linda Caradine-Poinsett, MBA, MJ, PhD, Executive Director
Mark Heiden, Associate Executive Director, Communications & Marketing
Melissa Kabadian, MA, CMP, Associate Executive Director, Education & Development
Carolyn Barth, Director, Public & Media Relations
Alethea Gerding, MA, Managing Editor, *Journal of Prosthodontics*
Jack Kanich, Finance and Administration Manager
Justin McDaniel, Membership Services Manager
Olivia Moukayed, Administrative & Education Coordinator
Adam Reshan, Director, Membership Services & Academic Relations
Lauren Swanson, Communications & Marketing Manager
Nathalie Williams, Director, Sections & Governance

Managing Editor

Lauren Swanson

Advising Editor

Mark Heiden

Design

Publications Associates, Inc.

Display Advertising

Lisa Trinkle, M.J. Mrvica Associates, Inc.
Phone: (856) 768-9360 Email: ltrinkle@mrvica.com

Classified Advertising

Visit Prosthodontics.org to download an insertion form. Email or fax the completed form to Lauren Swanson at lswanson@prosthodontics.org or (312) 573-1257. Classified ads are \$125 for the first 50 words and \$1 for each additional word for ACP members. The non-member rate is \$225 for the first 50 words and \$2 for each additional word. The minimum charge is \$125. Logos are an additional \$50, limited to one per ad and subject to approval. Payment by check, American Express, Visa, or Mastercard is required prior to placement.

The mission of the *ACP Messenger* is to inform readers about current prosthodontic trends, challenges, and successes. Statements of fact and opinion are the responsibility of the authors alone and do not imply an opinion on the part of the officers or the members of the ACP. The *ACP Messenger* annual subscription rate for members is \$45, which is included in membership dues. The U.S. subscription rate for Prosthodontic Forum Organization members is \$55 and \$65 for non-members. Canadian subscribers add \$5 each year; all other non-U.S. subscribers add \$10 each year.

The *ACP Messenger* (ISSN # 0736-346X) is published four times per year in the winter, spring, summer, and fall by the American College of Prosthodontists:

211 E. Chicago Ave., Suite 1000, Chicago, IL 60611
Phone: (312) 573-1260; Fax: (312) 573-1257
Email: acp@prosthodontics.org Website: Prosthodontics.org


© Copyright 2017 American College of Prosthodontists. All rights reserved. Materials may not be reproduced or translated without written permission. Contact the ACP for reprint permission.

Postmaster: Send address changes to the ACP Central Office at 211 East Chicago Avenue, Suite 1000, Chicago, IL 60611 or acp@prosthodontics.org.




Dr. Cynthia M. Aita-Holmes is Director of the Advanced Specialty Education Program in Prosthodontics at Fort Gordon, GA, and Membership Director for the Federal Services Region 6.

► Page 8



Joanne Balshi has served as Director of Marketing and Public Relations for the Pi Dental Center over the last thirty years. She is a freelance writer and authored *Smile Your Heart Out*, a coffee table book about the value of a healthy smile.

► Page 12



Dr. Thomas J. Balshi maintains a private practice in Fort Washington, Pennsylvania, where he blends clinical care with scientific research, education, and philanthropy.

► Page 12




Dr. Susan E. Brackett is President of the ACP and maintains a private prosthodontic practice in Oklahoma City.

► Page 20



Dr. Gerald T. Grant is a professor of prosthodontics and Interim Chair of the Oral Health and Rehabilitation Department at the University of Louisville.

► Page 16



Dr. Kerin M. Jamison is a third year resident at the Advanced Specialty Education Program in Prosthodontics at Fort Gordon, GA.

► Page 8



Dr. Mathew Kattadiyil is Professor and Director of the Advanced Specialty Education Program in Prosthodontics at Loma Linda University School of Dentistry, and Editor-in-Chief of the *ACP Messenger*.

► Page 6



QUINTESSENCE
INTERNATIONAL
PUBLISHING GROUP



Plan now to attend!

The 25th International Symposium on Ceramics
**Successfully Integrating the Best
of Traditional and Digital Dentistry**

JUNE 2-4, 2017 | SAN DIEGO, CA
Sheraton San Diego Hotel & Marina



Program Chair:
Avishai Sadan

Speakers

L. Bacherini • M. Blatz • A. Bruguera • G. Chiche • J. Choi • S. Chu •
V. Clavijo • S. Duarte • D. Edelhoff • M. Fradeani • I. Gamborena •
G. Gürel • N. Hayashi • P. Kano • P. Magne • E. McLaren • R. Mitrani •
M. Okawa • J.-H. Phark • A. Ricci • N. Sartori • A. Torosian • F. Vailati •
E. Van Dooren • N. Vlachopoulos • N. Yuasa

Spanish translation provided!

Register now at
www.quintpub.com/isc

Sponsor: 
ivoclar
vivadent
passion vision innovation


Academy
of General Dentistry™
PACE
Program Approval for
Continuing Education

ADA C.E.R.P.® | Continuing Education
Recognition Program

Best of both worlds

Mathew T. Kattadiyil,
DDS, MDS, MS, FACP
ACP Messenger Editor-in-Chief

Let's welcome this New Year with hope and excitement: hope that we continue to learn from our experiences, both good and bad, and excitement for the progress that will be made this year within our rapidly evolving specialty.

In a world that is torn apart by emphasis on differences, we strive to identify common goals and deliver life-changing treatments to our patients. It is vital that we maintain the spirit of collaboration and unity that makes prosthodontics a strong and appealing specialty.

Personally, I embrace digital technology and I am as excited as anyone else about its advances and applications. But I also believe that conventional clinical and laboratory techniques should not be forgotten in education. Only with hours of practice come the fine motor skills that need to be developed along with three-dimensional spatial visualization and tactile perception. These motor skills cannot be honed by navigating a computer mouse and should not become a lost art.

While we explore the potential of digital technology, conventional methods should still be taught so that the connection between the analogue and digital worlds continues. A blend of both worlds is a balanced approach and overreliance on one or the other could be counterproductive. The impact of using digital technology in the classrooms should not be overlooked as well, as it can impact student learning in a positive way.

This issue of the *ACP Messenger* is dedicated to blending ideas and perspectives from different worlds to form a more complete picture. Drawing on his

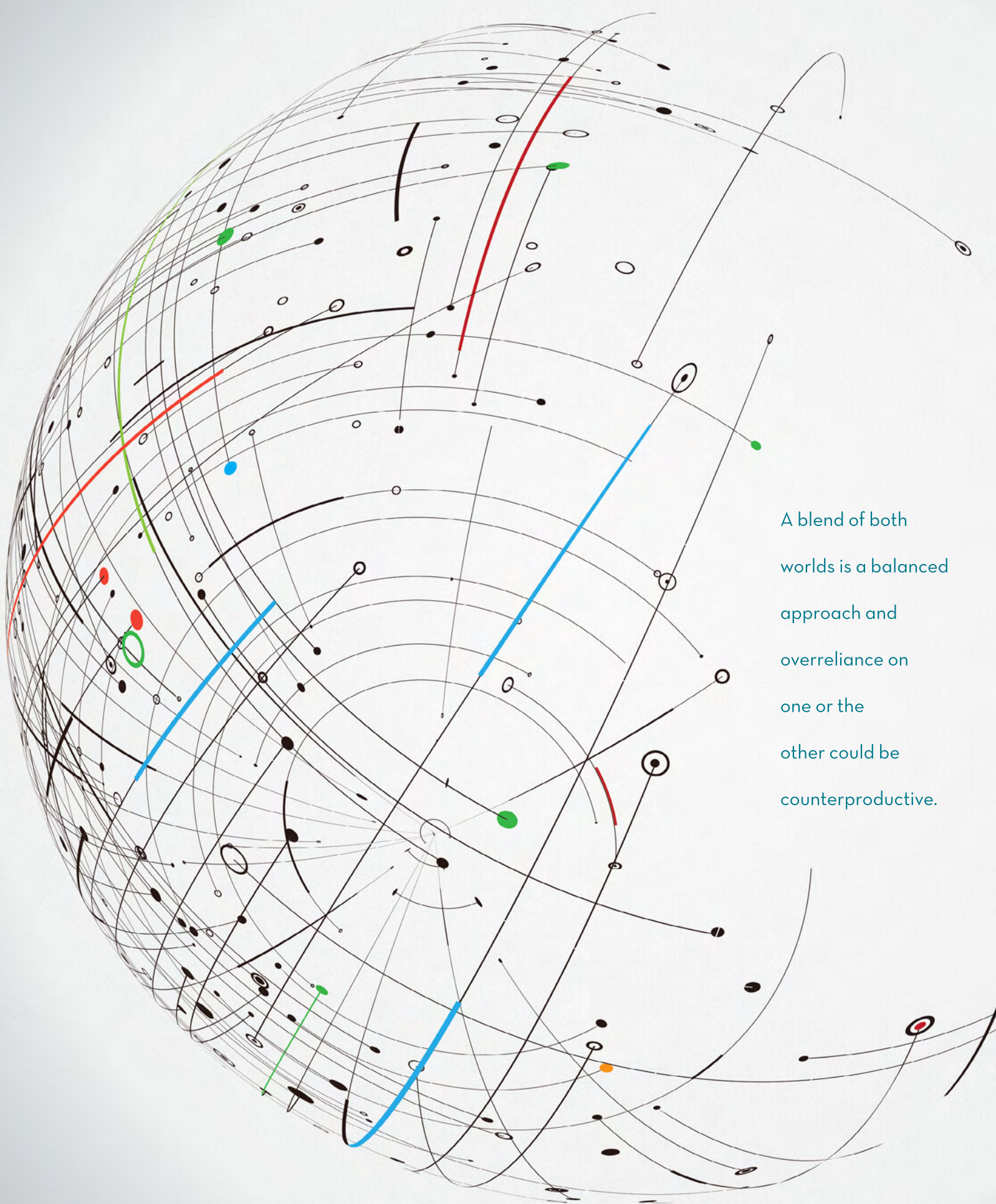
experience in the U.S. Navy and in dental education, Dr. Gerald Grant addresses the progress we have made in advanced digital dental technology in a thought provoking article about what patients and prosthodontists can expect from these developments.

Elsewhere in this issue, Drs. Kerin Jamison and Cynthia Aita-Holmes describe balancing the exacting demands of a patient with the exciting possibilities that prosthodontic treatment can offer. And Dr. Thomas Balshi talks about blending digital technology with implant prosthodontics to deliver a whole new smile to an energetic young man.

Finally, I would like to welcome Dr. Nadim Baba, the new *ACP* vice president, to our editorial team. For a glimpse of the enthusiasm that is coursing through our specialty, take a look at this issue's coverage of the recent *ACP* Annual Session in San Diego.

There is much that we have in common as prosthodontists. Blending advanced training with a commitment to continuous improvement means that we can deliver the best of both worlds to our patients. ■

DIGITAL



A blend of both worlds is a balanced approach and overreliance on one or the other could be counterproductive.

ANALOGUE

Treating the exacting patient

Kerin M. Jamison, DMD
Cynthia M. Aita-Holmes, DMD, FACP

As prosthodontists, we have all had the patient who walks into our office and asks for Julia Roberts' or Matthew McConaughey's smile. They want their teeth whiter, brighter, and straighter, they want to show more teeth, have longer or shorter teeth, they want to show less 'gums'... the list goes on.

The reality is that these patients rarely present with an ideal dental condition to easily achieve their desires. They may not have a normal smile line with the upper and lower jaws aligned in the correct position, an ideal architecture of the gum tissues, and centered teeth midlines. Our patients are unaware of the implications of these issues; therefore, they do not understand why their smiles cannot look like those of celebrities.

Celine arrived at the clinic with the chief complaint, "I don't like how my teeth look." Specifically, she requested whiter teeth, replacement of the discolored restorations on her anterior teeth, and smoothing of her uneven incisal edges. She was also unhappy with her long premolars and canines, the dark margins of her crowns, and the graying effect from her amalgam restorations. Finally, she wanted to replace her two missing teeth. After thorough clinical and radiographic evaluation, clinical photographs were obtained (Figure 1), and a diagnostic wax pattern was completed. A treatment plan was created based on her detailed list of requests.

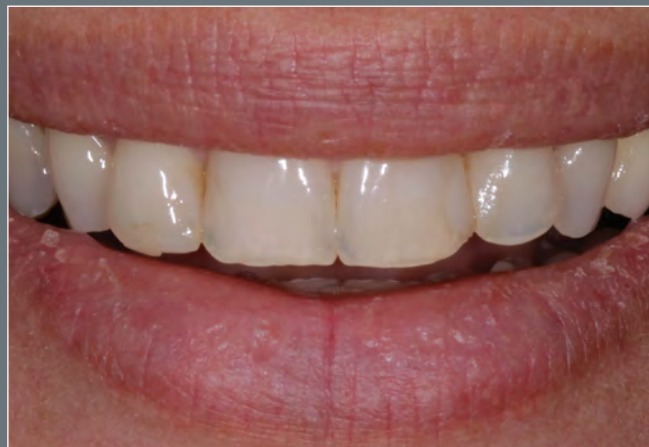
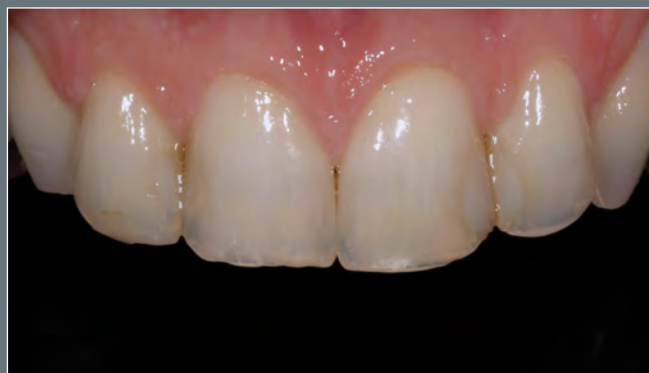
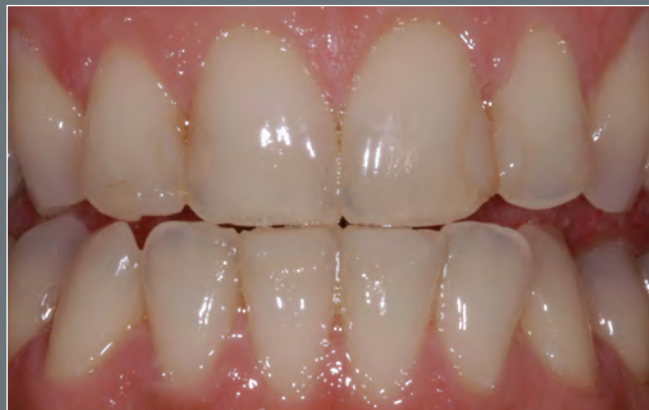What differentiates us as specialists, in part, is our ability to manage patient expectations and give them realistic outcomes based on our comprehensive knowledge of diagnosis and treatment planning. Fortunately, Celine presented with favorable jaw relations, Angle classification, smile line, gingival plane, vertical dimension and midlines. Therefore, the treatment should have been highly predictable and have a positive outcome. The only challenge that presented was the management of an esthetically conscious and exacting patient.

The treatment began with modified veneer preparations on teeth #7-10. After fabricating multiple sets of provisional restorations over several appointments and still not achieving patient satisfaction, it was clear that we would need to approach Celine's situation differently. Often, the patient struggled to articulate what she disliked. Consequently, we made the decision to digitally design various provisional restorations with different form, dimension, and contour and have the patient "try them on." This technique would allow the patient to clearly communicate her esthetic requests.

Using CAD software, stone models of the final preparations were scanned and six sets of veneers with differing forms were digitally designed (Figure 4). We also imported a model of the current provisional restorations into the software to maintain the desired

The views expressed in this article are those of the author(s) and do not necessarily reflect the official policy of the Department of Defense, Department of Army, US Army Medical Department, or the US Government.



Figs. 1a-c. Pre-treatment extraoral and intraoral views.

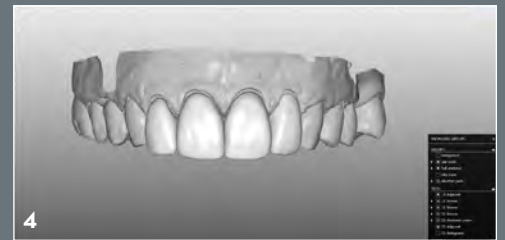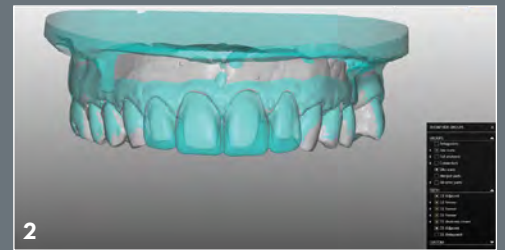

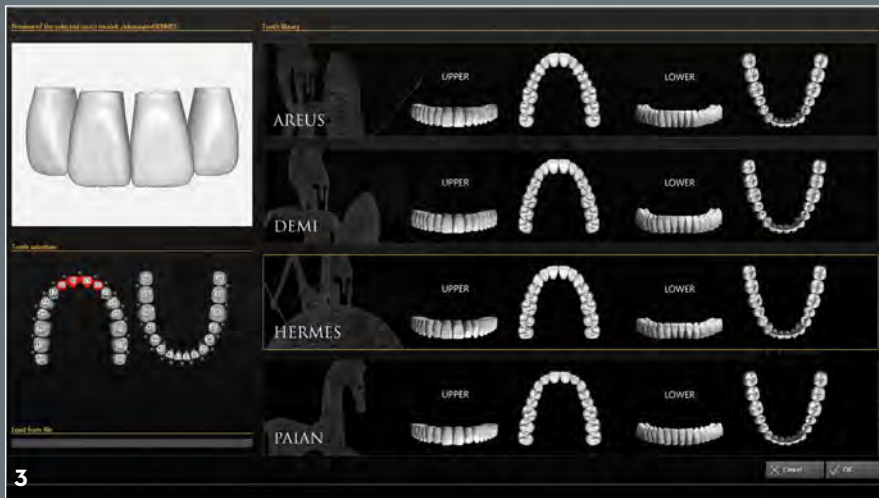
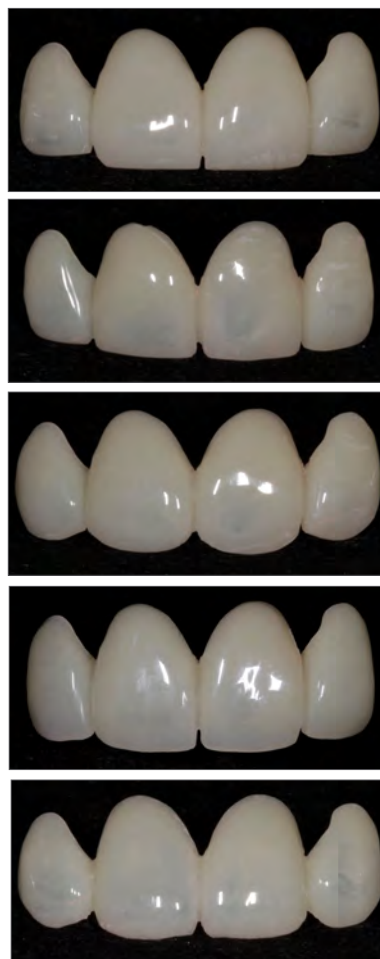Fig. 2: Scan of prepared teeth with an overlay of the provisional restorations.

Fig. 3: Library of different tooth forms.

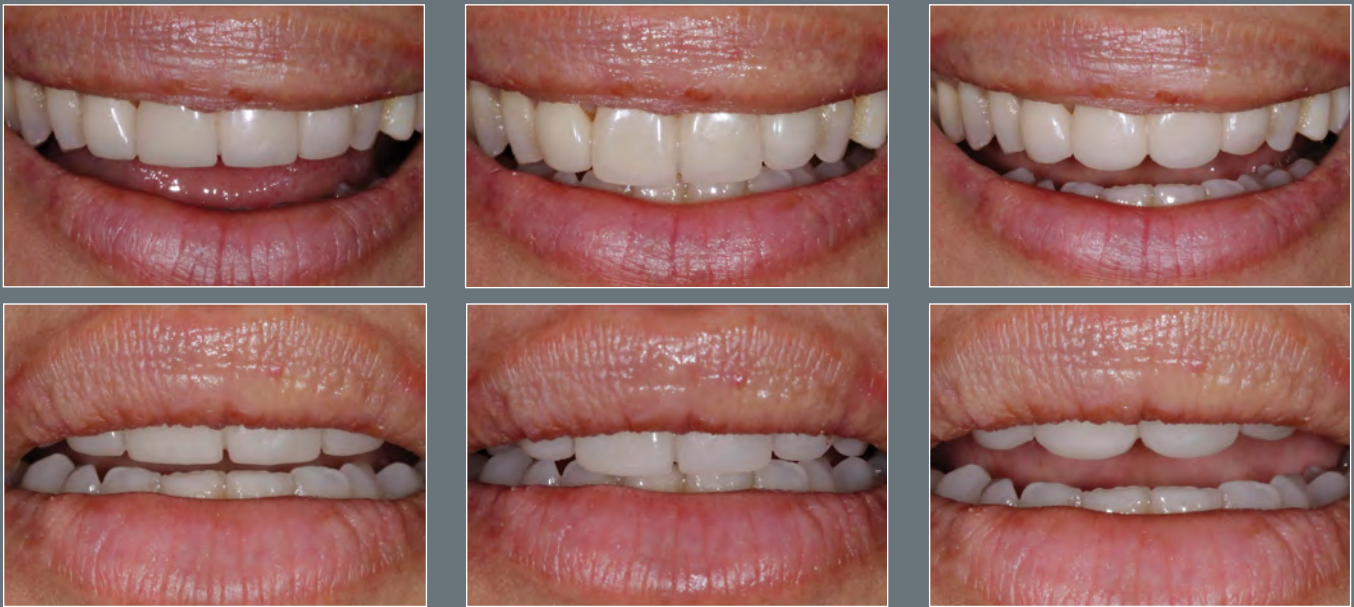Fig. 4: Digitally designed veneers.



incisal display (Figure 2). The software included multiple tooth form libraries, which made this process fairly quick (Figure 3). After the designs were complete, the four restorations were digitally splinted for ease of insertion and removal at the time of intraoral trial. They were then milled using a multi-layer polymethyl methacrylate (PMMA), finished, and polished (Figure 5).

At the following appointment, Celine assessed the different sets of diagnostic provisional restorations intraorally. Often we give our patients a hand mirror to evaluate their new restorations, and typically they will hold the mirror two inches away while pulling up their lip, leading to an inaccurate perception of their smile. To avoid this, we took extraoral photographs of Celine wearing each set of diagnostic provisional veneer restorations (Figure 6). Celine took a digital copy of these photographs home, giving her and her family the opportunity to objectively assess how others would perceive her smile.

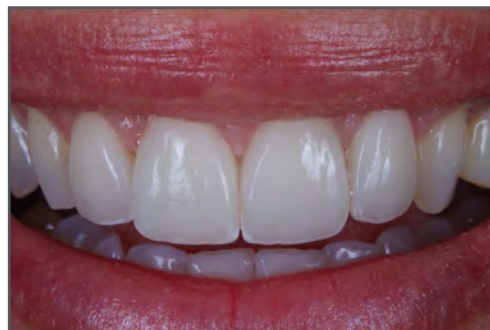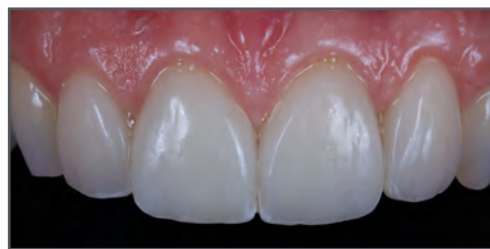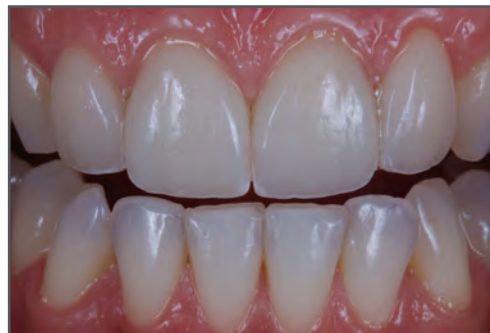Fig. 5: Five sets of PMMA splinted veneers with differing forms.



Figs. 6a-c: Diagnostic veneers - “straight,” “curved” and “round” designs in repose and smile.

We gave Celine an appropriate amount of time to determine which set of veneers best matched her esthetic preferences. After consideration of the different designs, we carefully fabricated the final restorations with her esthetic selection in mind.

In the end, the patient was extremely satisfied with the result (Figure 7). Using the above technique, we can provide esthetically oriented patients with an additional resource to evaluate the future restorations prior to their fabrication. As prosthodontists, we welcome the challenge of treating patients like Celine, who have a meticulous eye and scrupulous attention to detail – much like ourselves. ■



Figs. 7a-c: Extraoral and intraoral photographs of the final restorations.

Blending digital dentistry and implant prosthodontics

Thomas J. Balshi, DDS, PhD, FACP
Joanne Balshi

I first met Michael Frank on a job site where he was artistically and meticulously setting tile for a designer kitchen. Mike exuded energy and had an admirable work ethic. He had a good technician's eye and measurable pride in accomplishment, but the first time I saw him smile, I knew I could contribute something very valuable to the rest of his life.

At the age of thirty-three, Mike had a lot going for him. Besides his talent, he was a vivacious athlete with a great sense of humor and an uncommon warmth. Married with two young daughters, he worked a sixty-hour week and played soccer in his spare time. A smile was the only part of his signature that simply did not fit.

It was not difficult to convince Mike to allow me to evaluate him clinically and present him with a treatment plan. His evaluation revealed advanced periodontitis with extensive bone loss around his remaining teeth in both the maxilla and mandible, most likely the result of his heavy smoking and excessive consumption of soda for quite a few years.

Mike's clinical presentation demonstrated extensive flaring of the mobile anterior teeth. Diagnostic casts were made and articulated at the appropriate vertical dimension. These models were scanned digitally and the data files transmitted to a milling center for the construction of the fully milled monolithic PMMA resin provisional dentures. The anterior teeth were repositioned virtually in the 3-D planning software prior to production.



Fig. 1: Before

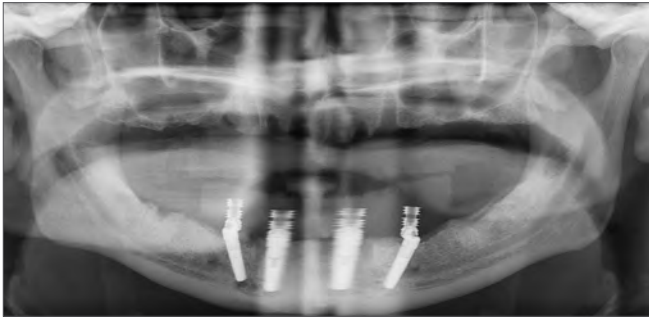


Fig. 2: Panoramic radiograph with multifunctional copings securing the Teeth-In-A Day® digital conversion prosthesis.

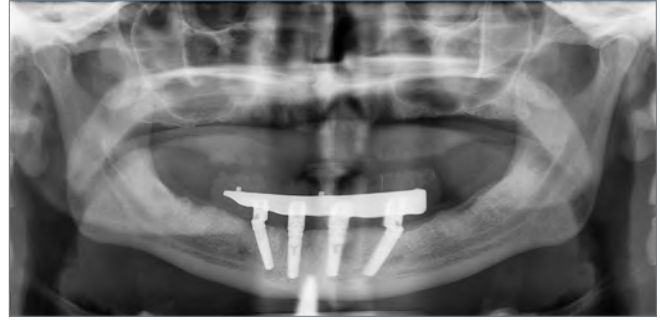

Fig. 3: Panoramic radiograph of the final All-On-4® fully milled screw-retained fixed prosthesis with milled titanium framework connecting the implants.

On the day of surgery, twenty cc's of blood were drawn and Platelet Rich Plasma (PRP) was produced for use during surgery. Local anesthesia was administered to both maxilla (upper jaw) and mandible (lower jaw), and all remaining teeth were extracted. Alveoloplasty was performed in preparation for future implant placement.

In the mandibular arch, full tissue flaps were reflected to identify the mental foramina. The anterior loop of the mental nerve was measured and noted. Beginning with the posterior implant placements in the mandibular right and left sides, a precision drill introduced the initiation of osteotomies (bone drilling). These were placed at a forty-five degree angle posterior tilt.

Four implants were coated with PRP and installed according to the All-On-4® treatment concept protocol. Autogenous (host) bone was gathered during all of the osteotomy preparation procedures and reintroduced into the extraction sites. Angulated

His evaluation revealed advanced periodontitis with extensive bone loss around his remaining teeth in both the maxilla and mandible, most likely the result of his heavy smoking and excessive consumption of soda for quite a few years.

multi-unit abutments were installed on the posterior tilted implants and 1mm straight abutments were placed on the anterior axially placed implants.

Following the Teeth in a Day® procedure, special multifunctional copings were installed with guide pins on all four abutments. The rubber dam was then installed to the base of the copings. Using auto-polymerizing acrylic resin, the monolithic conversion prosthesis was connected to the multifunctional copings. It was then removed and refined chairside.

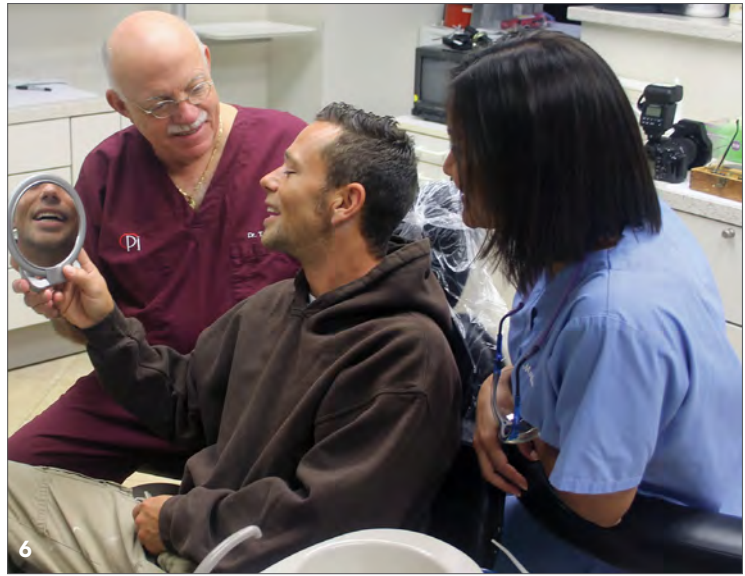
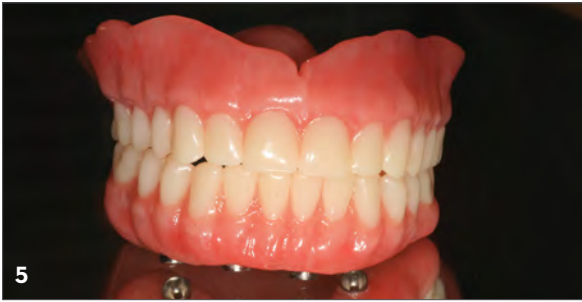
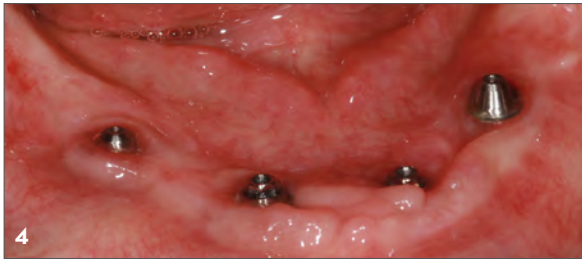Fig. 4: All-On-4® implants to support non-removable teeth in the lower jaw.

Fig. 5: Three months after implant surgery, the final digital upper denture and the All-On-4® monolithic fixed (non-removable) prosthesis for the lower jaw ready for delivery to the patient.

Fig. 6: Completion of treatment changes Mike's life.

Flap closure took place with multiple interrupted sutures. The Teeth in a Day® conversion prosthesis was then installed using prosthetic screws. The upper monolithic fully milled removable denture was relined, adjusted, and delivered at the same time.

Mike was given post-operative instructions and medications. One week following surgery, he returned for suture removal and minor adjustments to the maxillary immediate complete denture. At ten weeks post-surgery, the patient presented for final impressions, initiating the construction of his mandibular fully milled implant-supported prosthesis reinforced with a milled titanium frame. New occlusal records were made and a reline impression made in the maxillary removable immediate digital complete denture.



Fig. 7: After

Three weeks following the impressions, the final prostheses were delivered to an ecstatic patient whose sparkling personality and boundless energy went up still another notch, proof that at any age, a healthy, esthetic smile is a priceless asset. ■

Both arches were scanned and the data transmitted for the construction of a new fully milled monolithic maxillary removable digital denture and an All-On-4® final prosthesis with milled titanium framework for the mandibular arch.

Signature SMILES

Created uniquely for you.

"As pioneers in digital dentistry, we create beautiful smiles, by combining artistry, technology, with a passion for perfection in all we do."



Matt Stone

Camilla Carr

Lee Culp, CDT

Jack Marrano, CDT

Digital technology will continue to provide more efficient methods of communication and enhance the close cooperation and working relationship of the Prosthodontist - Technician team.

Contact us today, to learn how we can assist you in restorative excellence.



919.397.2972 | sculpturestudios.net

Advanced digital dental technologies

Gerald T. Grant,
BA, DMD, MS, FACP

Over the past few years the ACP has embraced, encouraged, and advocated for Advanced Digital Dental Technologies (ADDT). We have promoted prosthodontists as leaders, researchers, and educators, and we are developing curriculum to help our next generation of computer savvy dental students make the connection between technology and customized patient care.

The ACP recently published a glossary of ADDT terms to help us all communicate effectively. We have become more committed in our interactions with industry to promote standardization of scanning technologies, design software, digital manufacturing, and more appropriate restorative materials. In response, industry through mergers, collaborations, and restructuring of business strategies have made working outside a single system more available with more open systems and more reasonable workflows as well as the introduction of new materials. It is probably now safe to say that more so than any other dental specialty, we have embraced this technology, identified it as our own, and are making great strides to support Advanced Digital Dental Technologies in custom patient care. It is a credit to our ACP leadership over the past years that we have been able to position ourselves as leaders in ADDT in such a short time!

In addition, ADDT for custom patient care is seen in almost every dental-related journal both for dentists and laboratory technicians. ADDT has sparked a resurgence in our discussions on dental materials – are we using the right materials for the technology employed? There are articles that discuss workflow and laboratory communication in case studies, there are many articles that discuss the use of different digital manufacturing processes that can be adapted

for your private office (if you have a lot of time on your hands and you are willing to learn some rather sophisticated software), and there are also articles that present very complex patient situations as a function of simple remote communications with a laboratory using CBCT, intraoral scans, or scanned casts, and there are online meetings to plan and produce guides for complex bone and soft tissue manipulation with implant placements and restorations.

At this point, the ACP is well positioned to have prosthodontists recognized as the leaders in the use of ADDT for custom patient care, advocates for industry standardization, and promoters of research in the technology and materials. Through these efforts we will continue to influence the use of the technology by both prosthodontic and general private practitioners, educate our next generation of dentists, and drive the discussion on appropriate material advancements and technology development. However, as we push this technology, we will find that industry will drive the workflow and technology to address complex restorations such as full-mouth implant-supported restorations, planned by the laboratory with prescriptive information from CBCT and other scanning data with the target audience of the general dentist, as it is a more productive model for them – a very unnerving situation, as presently

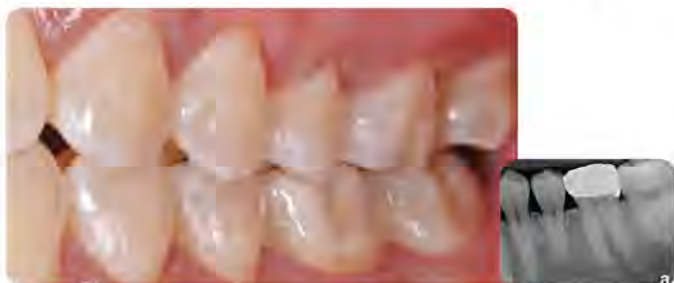there are a lot of decisions that need to be made that we as prosthodontists are uniquely trained to identify and address. We aren't there yet, but if you look at the case presentations that are being published, this is not an unlikely scenario and has historically been the evolution of many of our dental advancements.

The key is that with ADDT it is becoming possible to provide each patient with a predictable restoration as these technologies lend themselves to a basic standardization of methods, design, and production, regardless of the laboratory. This is not new, as it has been part of the way we have done business in the past and dental laboratories will find avenues to set themselves apart as experts in the field. However aside from the laboratory, prosthodontists need to also have

a clear vision of our position as specialists in this high tech approach to patient care and be able to define ourselves in the evolving practices around us.

So the question is "What now?" As prosthodontists, we have positioned ourselves as the emerging leaders of ADDT in application, development, education, research, and collaboration with industry. The questions we now need to ask are "How do further advances in ADDT affect us as a specialty as we define ourselves today?", "How do we need to evolve?", and "Where do we want to position ourselves as a specialty in this high tech future?" This is the conversation we must have about what will define prosthodontics in the future as technology continues to progress. ■

High End Full Zirconia Crowns and Bridges!



KATANA UTML Full Zirconia Crown with custom staining / Tooth #19
Dentistry by Ariel J. Raigrodski, DMD, MS, FACP, Lynnwood, WA

Cusp Dental Laboratory Provides:

- Accurate margins
- Superior adjacent and occlusal contacts
- Advanced esthetic laboratory procedures

\$167/single crown

Bridge connection \$15 each / **Custom staining is additional.**

KATANA™ UTML
550 MPa Flexural Strength



Ultra Translucent Multi-Layered

Suitable for anterior crowns and bridges up to 3 units, inlays/onlays, and posterior single unit crowns

KATANA™ STML
750 MPa Flexural Strength



Super Translucent Multi-Layered **NEW 2017 KATANA STML Shades are now available!**

Suitable for posterior crowns and bridges up to 3 units

KATANA™ ML & HT
1100 MPa Flexural Strength



ML: Multi-Layered / HT: High-Translucent Monolithic Shaded

High strength zirconia is suitable for crowns and bridges 4 or more units

Contact us at **888-267-0660** toll free, **781-388-0078** or info@cuspdenal.com

Review our work at www.cuspdenal.com

KATANA is a trademark of Kuraray Noritake Dental Inc.

Powerful CAD tools without complexity – NobelDesign™

For decades, Nobel Biocare has been redefining the work of dental technicians around the world with NobelProcera. The system became a benchmark, paving the way to accurate, consistent, and efficient manufacturing of dental prostheses.

Because of NobelProcera, new materials once thought impractical and difficult to work with became mainstay, enabling restorative solutions with high strength and esthetics.

Now, Nobel Biocare introduces the next benchmark, the NobelDesign software, which combines advanced CAD tools with an intuitive and adaptive interface. With NobelDesign, dental laboratories gain access to the latest NobelProcera restorations, enabling them to deliver a wider range of precise, computer-engineered prosthetic solutions to dental clinicians and their patients.

Familiar friend, powerful ally

The intuitive NobelDesign interface supports a simplified workflow that allows dental technicians to create, scan, and manage multiple cases with ease. Best of all, it adapts to each user's preferred way of working, increasing workflow efficiency over time.

For many dental technicians, NobelDesign will seem familiar and, at the same time, fresh. NobelDesign integrates well-known exocad CAD tools for the efficient design of cemented and screw-retained restorations, accessed via the NobelDesign Cockpit.

Creating outstanding restorations made easy

When it comes to creating restorations, there is real power in the NobelDesign design toolbox. Numerous robust and automated applications are included in the base module of NobelDesign, assisting dental technicians with the design of crowns, abutments, and bridges. Tools are also available that provide users with insight into how their restorations will look and perform in patients' mouths.

Once cases are set up and scanned into NobelDesign, libraries filled with archetypal teeth, crowns, bridges, and implants provide excellent starting points from which dental technicians create their own patient-specific restorative solutions.

Another way to accelerate the design workflow is NobelDesign's Mirror Tooth function. With it, dental technicians use a mirror image of the shape and anatomy from the contralateral quadrant of the target tooth. This copy, or diagnostic tooth, forms the basis upon which they design the patient-specific restoration.

Esthetics are important, but function is the ultimate goal. For testing function in the virtual environment, NobelDesign offers the Virtual Articulator feature. This application allows users to view their designs in a patient's complete dentition. Articulated movements

Find out more at nobelbiocare.com/nobeldesign.



Nobel Biocare was invited to submit this feature as part of their sponsorship of the Annual Session.

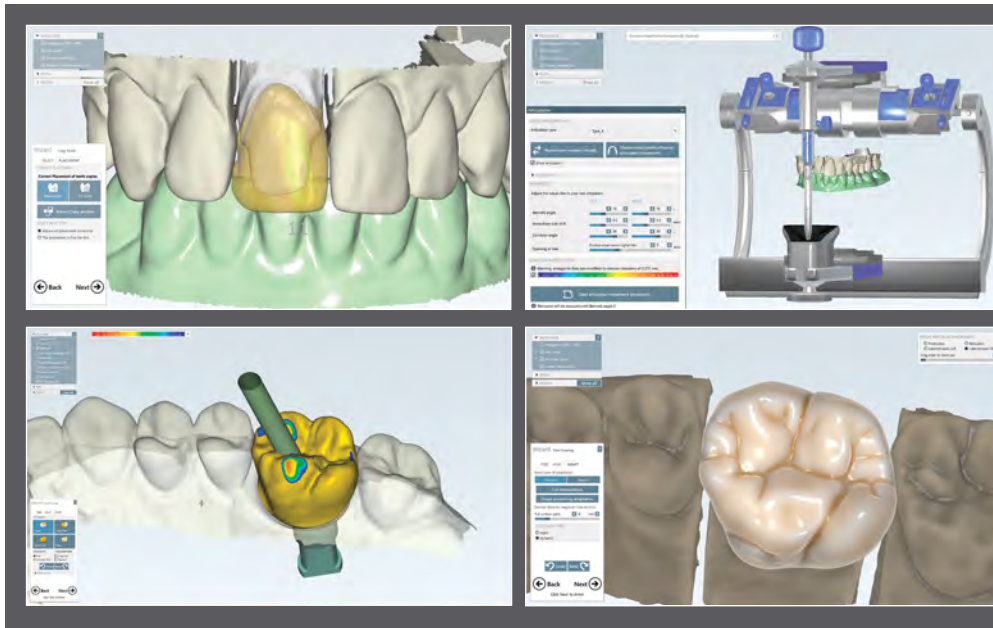


Fig. 1: Mirror Tooth accelerates the design process by starting with a mirror copy of the target contralateral tooth.

Fig. 2: Angulated Screw Access allows technicians to reposition the screw access exit hole to a more favorable location within the restoration.

Fig. 3: With the Virtual Articulator the user digitally guides a restoration through excursive movements to achieve accurate occlusion.

Fig. 4: The TruSmile feature visualizes fissure design and tooth shape in photorealistic renderings.

visualize and predict occlusion, helping dental technicians confirm prosthetic fit.

During the design process for screw-retained restorations, the screw access hole is typically predetermined based on implant placement. However, in cases where esthetics would be sacrificed or fixation of the restoration could be difficult, a dental technician can adjust the angulation of the screw access hole within the restoration. With this option, screw access can be angulated from 0° to 25° in a 360° radius. This can enable the use of a cement-free restoration in situations where it might previously have been impossible.

Another tool allows users to create a cutback for their restoration to aid with veneering. With NobelDesign's Shrinking feature, the technician can easily select which area to cut back, depending on whether they want to fully or partially veneer the restoration.

During the final stages of restoration design, dental technicians can employ the exocad® TruSmile technology incorporated into the software. This feature renders restorations with photographic realism, displaying final tooth shape and fissure design. This is virtual reality at its best; the closest representation of how a restoration will look once seated in the patient's mouth.

The future of CAD/CAM

As the latest milestone in Nobel Biocare's ongoing innovation in CAD/CAM, all forthcoming NobelProcera innovations will only be available through NobelDesign. While current NobelProcera CAD users can continue to use their existing systems, NobelDesign will offer an increasing number of advantages. Additional features are already in development, as is enhanced integration with other solutions.

NobelDesign is accessible only in combination with the highly accurate NobelProcera 2G Scanner, and is available on an annual subscription basis. This gives dental laboratories added flexibility, and helps them avoid a sizeable one-time payment to start.

World-class support, high-end results

As a leading dental solutions provider, Nobel Biocare offers unparalleled support to its dental partners with NobelDesign. Support in terms of customer service, training, and restoration quality, all delivering priceless peace-of-mind to dental professionals.

Based on user feedback, the suite of applications available in NobelDesign not only assists dental technicians in their pursuit of prosthetic perfection, it makes their work easier and more rewarding. ■

Goals

Susan E. Brackett,
DDS, MS, FACP
ACP President

Becoming President of the American College of Prosthodontists is quite a unique phenomenon. Even though you know it's coming, it still overwhelms you. As a BIG fan of college sports, I recognize the importance of teamwork, and fortunately, I have an outstanding team to support me - the officers, the Board of Directors, the ACP staff, and you, the members.



Every President has goals for the College to achieve, and I certainly have developed some areas I would like to emphasize during my term. First, I would like to welcome our new Executive Director Dr. Linda Caradine-Poinsett to the ACP. She is exceptionally qualified and highly accomplished, and I hope to use my experience and knowledge of the College to help her become comfortable with its history and its future goals.

I also hope to build on the member proposition the staff developed recently. When exploring the value of the ACP to members, the staff evaluated and compared a number of organizations and then proposed this simple explanation for belonging to the College:

“The ACP is the organization that represents the specialty of prosthodontics.”

I would like to encourage all of you to embrace this statement and play a role in the recruitment and retention of friends and colleagues to join you as members of the ACP.

To the new diplomates, the recent graduates, and the residents, I would like to say first of all “Congratulations!” You have chosen a wonderful profession where you will have an opportunity to improve your patients’ lives, and I hope you find your career in prosthodontics as rewarding and fulfilling as I have. More than anything else, you are the

specialty's future, and we need you to help guide this organization as we plan for the future. So, please be engaged. There are a lot of demands on your time at this point; so, start small – maybe help with a National Prosthodontics Awareness Week project, apply for the ACP Spokespersons Network, get involved with your state section, maybe become an officer, or serve on an ACP Committee. You are our future leaders, and we need your input and involvement.

CODA passing our revised standards in 2015 was a significant milestone. It means that prosthodontists will no longer be considered “second class citizens” in the surgical placement of dental implants, but it is not enough. In order to consolidate this victory, we must update and revise our *Parameters of Care*. The *Parameters of Care* define the scope of prosthodontic practice and include the procedures we perform every day in our practices. In 2017,

a Task Force will manage these revisions and publish the latest version, solidifying our position in the world of dental implants and digital dentistry.

One other area to consider during my term involves governance. Ten years ago the College voted to disband the House of Delegates and introduced a system based on regional representation with hopes of encouraging more grassroots participation and input from our members. It seems after a decade that now is an appropriate time to closely look at our current governance structure, evaluate it, and determine if it is adequately serving our needs – or if there is another more effective system to consider. So we will be conducting a governance audit in 2017.

Thank you for this tremendous opportunity to serve the specialty of prosthodontics, the American College of Prosthodontists, and its members. ■



The American College of Prosthodontists advocates for the valuable role that prosthodontists play on the dental team. **National Prosthodontics Awareness Week (NPAW)** focuses on raising public awareness about prosthodontics and the critical importance of a healthy mouth.

**Save the date
to celebrate!
April 2-8, 2017**

GET INVOLVED:
Prosthodontics.org/NPAW

RAISE AWARENESS:
GoToAPro.org

ACP | AMERICAN COLLEGE OF
PROSTHODONTISTS
Your smile. Our specialty.®

Tomorrow's solutions in San Diego

Everything is changing in the art and technology of prosthodontics, and the ACP Annual Session was built with that in mind. Dr. Carl F. Driscoll, ACP President and Dr. John R. Agar, Program Chair welcomed nearly 1,100 professional attendees - the second highest in ACP history - to San Diego to hear about the very latest breakthroughs in health, function, and beauty, direct from the forefront of clinical practice.



THANK YOU TO ALL
OUR SPONSORS



John J. Sharry Research Competition

Combined with a scientific presentation from Proctor & Gamble, a major supporter of the ACP research mission, Sharry presentations included cutting edge research that covered a wide range of topics.

“The Sharry competition continues to grow and I am amazed by the quality of the presentations this year,” said Dr. Radi Masri, Chair, ACP Research Committee. “The increased competition made it harder to select the winners because all the projects presented had exceptional merit and a clear translational and evidence-based foundation. This is a strong indicator that prosthodontic research continues to evolve to address critical problems affecting patients’ oral health.”



Pictured from left to right: Dr. Virginia L. Hogsett, Dr. Craig L. Sikora, and Dr. Hannah C. Drew

1ST PLACE: Dr. Craig L. Sikora

University of Illinois at Chicago (2016)

Wear and Corrosion at the Titanium-Zirconia Implant Abutment Interface

2ND PLACE: Dr. Virginia L. Hogsett

University of Illinois at Chicago (2016)

Outcomes of Implant-Fixed Complete Dental Prostheses: A Comparison of Metal-Acrylic, Milled Zirconia, and Retrievable Crown Prostheses

3RD PLACE: Dr. Hannah C. Drew

United States Air Force (2017)

Development of an Antimicrobial Soft Denture Liner with in situ-Generated Silver Nanoparticles for the Prevention and Treatment of Candidiasis

Awards of Distinction



Distinguished Lecturer Award
To Dr. Thomas D. Taylor, pictured here with Dr. Carl F. Driscoll (right) and Dr. John R. Agar (left).



Educator of the Year Award
To Dr. Kenneth A. Malament, pictured here with Dr. Driscoll and Dr. Heather Joan Conrad (right).



Clinician/Researcher Award
To Dr. Gerald T. Grant, pictured here with Dr. Driscoll and Dr. Cortino Sukotjo (right).



Dental Technician Leadership Award
To Mr. Dennis Lanier, pictured here with Dr. Driscoll and Mr. Steven Pigiacci (right).



Major General (Retired) Bill B. Lefler Federal Services Award
To Dr. Thomas G. Reddy, pictured here with Dr. Driscoll and Dr. Servando Ramos (right).



Dan Gordon Award
To Dr. Thomas J. Balshi, pictured here with Dr. Driscoll.



President's Award
To Dr. John R. Agar, pictured here with Dr. Driscoll.

Private Practice Award



Region 2 - Eastern
To Dr. Michael T. Singer, pictured here with Dr. Driscoll (left) and Dr. Robert M. Bentz (right).



Region 3 - Central
To Dr. Timothy A. Peterson, pictured here with Dr. Driscoll and Dr. John D. Ball (right).



Region 4 - Rockies/Plains
To Dr. Khaldoun F. Ajlouni, pictured here with Dr. Driscoll and Dr. Alvin G. Wee (right).

Presidential Citations



Dr. Leon Assael was honored for his visionary leadership in supporting the specialty of prosthodontics and the Standards for Advanced Education in Prosthodontics.



Mr. Scott Root was honored for his visionary leadership in supporting and advancing the specialty of prosthodontics.



Dr. Steven J. Sadowsky was honored for his outstanding dedication, service, and leadership as Chair of the annual Prosthodontic Review Course from 2012-2016.

Honorary Member Recognition



Dr. Edmond Bedrossian, pictured here with Dr. Carl F. Driscoll (left) and Dr. Frank J. Tuminelli (right).



Dr. Isabelle Denry, pictured here with Dr. Driscoll (left).



Dr. Van P. Thompson, pictured here with Dr. Driscoll (left).

ACPEF Founders Society Award



Dr. Leonard B. Kobren, pictured here with Dr. Lyndon F. Cooper (left).

Dr. Leonard B. Kobren was recognized as the recipient of the ACPEF Founders Society Award, which honors individuals who have made a significant impact on the growth and development of the Foundation and demonstrated an extraordinary level of commitment to the advancement of the specialty.

Dr. Kobren has played a significant role in the development of the Foundation for over 15 years serving as one of the first Chairs of the Annual Appeal, an active supporter, and a member of the Foundation Board for nine years.

Special Thanks



The American College of Prosthodontists would like to recognize the generosity of Nobel Biocare as the primary sponsor of the 2016 Annual Awards and President's Dinner.



Award recipients participated in the event through the generosity of Ivoclar Vivadent.



Special thanks to Henry Schein for their support of the Distinguished Lecturer, Educator of the Year, Clinician/Researcher, and President's Awards.

Resident & Dental Student Poster Session Competition


Over 120 poster presentations highlighted the scholarly activity of residents and dental students. The posters varied between presentations of research results, clinical outcomes, laboratory techniques, and more. The 2016 Poster Session Competition was made possible through the support of the ACP Education Foundation. Entrants are pictured with Dr. Caroline T. Nguyen, Poster Session Chair. Congratulations to the following resident and dental student winners!

Resident Competition




Dr. Peter D. Walker
University of British Columbia (2017)
"CAD-on" Crowns - A Fracture Mechanics Characterization


Dental Student Competition



Mr. Amin Nasehi
University at Buffalo (2017)
Development of Rubrics for Quantitative Assessment in Preclinical Fixed Prosthodontics Using a Comparison Software



Dr. Geoffrey L. Ward
United States Navy, Naval Postgraduate Dental School (2017)
Comparison of Shear Bond Strength of Milled PMMA to Reline Material with Different Surface Conditioning Chemical Properties



Ms. Stella C. Stavrou
Stony Brook University (2017)
How Good Is Goodacre: A Literature Review of Goodacre's "The Prosthodontic Management of Endodontically Treated Teeth", Part 2



Dr. Edmond A. Bedrossian
University of Washington (2018)
A Technique to Correct Discrepancy of Anterior-Posterior Tooth Position of an Immediate Complete Denture



Mr. Robert G. Cox
University at Buffalo (2017)
Quality of Tooth Preparations for Monolithic Zirconia Restorations Submitted to Local Dental Laboratories

New ACP 2017 Officers and Board Members



Dr. Susan E. Brackett was installed as President of the American College of Prosthodontists. In 1998, following a long and successful career in academics, she joined an established prosthodontic private practice in Oklahoma City. In 2013, the ACP Education Foundation recognized Dr. Brackett's service to the organization with the Founders Society Award. She is a Diplomate of the American Board of Prosthodontics and a Fellow of the American College of Dentists and of the American College of Prosthodontists.



Dr. Robert M. Taft was installed as President-Elect of the American College of Prosthodontists. He is Professor and Chair of the Department of Comprehensive Dentistry at the University of Texas Health Science Center School of Dentistry in San Antonio, Texas. He is a Diplomate, Board Examiner, and Immediate Past-President of the American Board of Prosthodontics, Fellow of the American College of Prosthodontists and Academy of Prosthodontics, Past President of the American Academy of Maxillofacial Prosthetics, and CODA site visitor, along with many other roles.



Dr. Nadim Z. Baba was installed as Vice President of the American College of Prosthodontists. He serves as a Professor and Director of the Hugh Love Center for Research and Education in Technology at Loma Linda University and maintains a part-time private practice in Glendale, CA. He previously served on the ACP Board of Directors as the Region 5 Membership Director from 2010-2014. He also served as Co-Chair of the ACPEF Annual Appeal Committee from 2012-2013. He is a Diplomate of the American Board of Prosthodontics and a Fellow of the American College of Prosthodontists.



Dr. Lars Bouma was installed as Continuing & Professional Education Division Director. After eleven years of service in the Air Force, he now maintains a full-time private practice limited to prosthodontics in Oklahoma City. He also teaches at the University of Oklahoma. He has previously served as an ACP State Section President for Nebraska and Oklahoma, and recently completed his second term as the Region 3 Membership Director of the ACP Board of Directors.



Dr. Alvin G. Wee was installed as Education & Research Division Director. He serves as Section Head of Maxillofacial Prosthodontics at the Veterans Affairs Nebraska-Western Iowa Health Care System in Omaha, Nebraska. He currently serves as Treasurer for the International Academy of Oral and Facial Rehabilitation, Recording Secretary of the American Academy of Maxillofacial Prosthetics, Assistant Editor of the *Journal of Prosthetic Dentistry*, and also Associate Editor for the *Journal of Otolaryngology - Head & Neck Surgery*.

ACP EDUCATION FOUNDATION

Advancing prosthodontics through education and research

Thank you to our corporate supporters
who have contributed to the
2016 ACPEF Annual Appeal.

GOLD LEVEL



SILVER LEVEL



BRONZE LEVEL



DONOR LEVEL



OUR COMMUNITY

New ACP 2017 Officers and Board Members




Dr. Paivi A. Samant was installed as Region 2 Membership Director. She maintains a private practice in Gainesville, FL where in addition to prosthodontics, she also specializes in dental sleep medicine. She is also affiliated with the University of Florida College of Dentistry. She is a recent past president of the Florida Prosthodontic Association.



Dr. B. Todd Pickle was installed as Region 4 Membership Director. He maintains a private practice in Colorado Springs, CO. He also founded the Pickle Prosthodontics Continuing Education Center, where he provides lectures, hands-on labs, and patient treatment clinics. He is a Diplomate of the American Board of Prosthodontics and a Fellow of the American College of Prosthodontists.



Dr. Cynthia M. Aita-Holmes was installed as Region 6 Membership Director. She is a Colonel in the U.S. Army Dental Corps and serves as Program Director for the Advanced Education Program in Prosthodontics at Fort Gordon, GA. She is a Diplomate of the American Board of Prosthodontics and a Fellow of the American College of Prosthodontists.



Dr. Caroline T. Nguyen was installed as Region 7 Membership Director. She is an assistant professor at the University of British Columbia, as well as practices as a maxillofacial prosthodontist and serves as the Provincial Practice Leader for the prosthodontics division of the British Columbia Cancer Agency. She is the current President for the Association of Prosthodontists of Canada. She has previously served as the Chair of the ACP Poster Session and Table Clinics. She is both a Fellow of the Royal College of Dentists of Canada and of the American College of Prosthodontists.

Dr. Carl F. Driscoll will remain an active member of the ACP Board of Directors by serving as Immediate Past President for the next year. **Dr. Stephen D. Campbell** and **Dr. Donald A. Curtis** have been elected as Past Examiners on the ACP Council for the American Board of Prosthodontics. **Dr. Mathew T. Kattadiyil** has been elected as the new Examiner (Director) Elect of the American Board of Prosthodontics.

DIGITAL WORKFLOWS: FROM SIMPLE TO COMPLEX REHABILITATION

Digital Dentistry Symposium

Feb. 21-22 • Chicago

Before the Midwinter Meeting
of the Chicago Dental Society

Breakout sessions for intermediate, advanced, and expert users.



Your smile.
Our specialty.®

SPONSORED BY:



Register at Prosthodontics.org



New Diplomates of the American Board of Prosthodontics

Congratulations to the Class of 2016!

Dr. Salem Akkad
 Dr. Khaled A. Al-Abdullah
 Dr. Faisal D. Alqarni
 Dr. Hamad S. AlRumaih
 Dr. Celin Arce
 Dr. Renos Y. Argyrou
 Dr. Amy S. Au
 Dr. Damian L. Black
 Dr. Jay E. Boatwright
 Dr. Andrew J. Bock
 Dr. David B. Burnham

Dr. Geoffrey R. Cunningham
 Dr. David P. Donatelli
 Dr. Alicia Estrella
 Dr. James C. Fischer
 Dr. Christine A. Fortmann
 Dr. Chin-Chuan Fu
 Dr. John H. Gittins
 Dr. Christopher M. Hamlin
 Dr. Ashley N. Harris
 Dr. Ashley B. Hoders
 Dr. Alice W. Hsieh

Dr. Ibrahim A. Ismail
 Dr. Amit S. Kamat
 Dr. Yash T. Kapadia
 Dr. Christopher S. Kaplafka
 Dr. Jee Y. Kim
 Dr. Jiyeon J. Kim
 Dr. Gabriela F. Lagreca
 Dr. Michael J. Lassle
 Dr. Gregory H. Lehnes
 Dr. Ketu P. Lincoln
 Dr. James G. Linkous

Dr. Garin Liu
 Dr. Edward G. Owens
 Dr. Miguel J. Pappaterra
 Dr. Joshua E. Perry
 Dr. Kamolphob Phasuk
 Dr. Man Y. Pun
 Dr. Evan B. Rosen
 Dr. Priscilla Kia Suan Sia
 Dr. Goth KF Siu
 Dr. Yi-Ming Yang
 Dr. William H. Young



ACP Represented at ASDA National Leadership Conference

Dr. Stuart R. Schelkopf, a third year resident at the University of Illinois at Chicago, represented the ACP at the 2016 National Leadership Conference of the American Student Dental Association.

This conference, which brought more than 700 dental students to Chicago, is a source of personal and professional development: career planning, business and financial leadership, advocacy, professional issues, chapter leadership, and management. Students learned about residency programs, careers in prosthodontics, and the benefits of ACP student membership.

Upcoming Events



**Digital Workflows:
 From Simple to Complex
 Rehabilitation**
 Digital Dentistry Symposium
 Chicago
 Feb. 21-22, 2017
 Prosthodontics.org

**Academy of
 Osseointegration
 Annual Meeting**
 Co-sponsored by the ACP
 Orlando
 March 15-18, 2017
 osseo.org

**National Prosthodontics
 Awareness Week**
 April 2-8, 2017
 Prosthodontics.org/NPAW

47th Annual Session
 San Francisco
 Nov. 1-4, 2017
 acp47.com



In the January Journal of Prosthodontics

A recent review of the scientific literature indicated that 30% to 50% of patients do not use their removable partial dentures (RPDs) due to technical aspects of therapy. An emphasis on patient-oriented outcomes may provide a better level of evidence and increase the clinical relevance of research studies. This is particularly important due to the reported disagreement among dental professionals and patients regarding esthetic and functional results of prosthodontic therapy. Therefore, Dr. Ingeborg De Kok and colleagues conducted a systematic review to identify and summarize the evidence regarding patient-oriented outcomes of satisfaction and oral health-quality of life (OHQoL) related to RPD therapy.

The authors found a paucity of detailed investigations concerning patient-centered outcomes of RPD therapy. Improvement in OHQoL or satisfaction following provision of RPDs has not been consistently reported. Little evidence supports any association between patient-reported quality of life or satisfaction with technical or biological parameters of therapy. In light of the limited positive improvement in patient-reported outcomes associated with conventional RPD therapy, and given that recent investigations using dental implants to stabilize RPDs demonstrated improved OHQoL, further investigation and innovation in the treatment of partial edentulism is recommended. The authors also suggest that the clinician should “approach RPD wearers with remarkable empathy and... emphasize the need for continuous management of their partially edentate condition.”

This review was supported by an educational grant from GlaxoSmithKline to the ACP Education Foundation.

De Kok IJ, Cooper LF, Guckes AD, et al: Factors influencing removable partial denture patient-reported outcomes of quality of life and satisfaction: A systematic review. J Prosthodont doi:10.1111/jopr.12526

Welcome New Members

September 2016 – December 2016

New Advanced Program and Graduate Student Alliance Affiliates

Dr. Abdulaziz Alghawazi
Dr. Yi Luo
Dr. Nicole Passia

New Dental Technician Alliance Affiliate

Mr. Kyle Alan Bennett

Reinstated Dental Technician Alliance Affiliate

Mr. Julian A. Infante

Reinstated Fellow

Dr. Hyejin Kwak
Dr. Bryan A. Williams

New Global Alliance Affiliates

Dr. Qingsong Jiang
Dr. Alejandro Mora
Dr. Christine J. Wallace

Reinstated International Fellow

Dr. Amal Rashad Abualsamh

Reinstated International Members

Dr. Yvonna V. Hrabowsky
Dr. Manuel Romo Garcia Rulfo
Dr. Brent P. Winnett

Reinstated Members

Dr. Zeina Al-Salihi
Dr. David P. Brock
Dr. Christopher Dindal
Dr. David R. Jimenez
Dr. Soon No Kim
Dr. Glena Patricia Millan
Dr. Ryan C. Lewis
Dr. Shweta A. Tawde

New Predoctoral Alliance Affiliates

Ms. Ashley N. Beck
Mr. Borys L. Bilaniuk

Mr. Nathaniel Chertok
Mr. Michael B. Evans
Mr. Joseph S. Finelli
Ms. Siera C. Hardy
Mr. Benjamin A. Kordusky
Ms. Catherine Lee
Mr. Christopher S. Mallow
Ms. Yulia Meadows
Ms. Jasmine C. Mohandesi
Mr. Brooks A. Paine
Ms. Angela M. Pelehac
Mr. Michael R. Petrides
Ms. Kathleen G. Schessler
Mr. James Shane Young

New Resident/Graduate Student Members

Dr. May N. AlAidrous
Dr. Mahdi Ali
Dr. Elahe Behrooz
Dr. Michael J. Lee
Dr. Joshua M. Nardone
Dr. Brandon C. Peters

IN MEMORIAM

The College and Board of Directors remember the following colleagues:



Dr. Juliet Kafka Bergen
Dr. Benjamin E. Dooley*
Dr. Robert Jeronimus*
Dr. David R. Jordan*
Dr. Keki R. Kotwal
Dr. Norman D. Lieb
Dr. Donald Lundquist*
Dr. Wallace W. Luther*
Dr. Dorsey J. Moore*
Dr. Howard E. Neely*
Dr. Frederick A. Pflughoef*
Dr. Dale E. Smith*
Dr. Melissa N. Tormos
Dr. Robert F. Wright



In their honor, the College has made a contribution to the ACP Education Foundation.

** denotes Charter Member*

Job Opportunities

California (Palm Desert) - A terrific opportunity for a skilled prosthodontist associate. Preferably board-certified, with strong communication skills. Needed in established multi-specialty Palm Desert, CA office established in 1992. High income potential for only working one day per week. Please email cover letter and CV to golfinthedesert@gmail.com.

Colorado (Greenwood Village/Denver) - An opportunity exists to join an established comprehensive prosthodontic practice in Greenwood Village / Denver, Colorado. Associateship with a view toward partnership. Referral based, fee for service, fixed, removable, implant and aesthetic dentistry. To learn more, visit www.aldoleopardi.com and www.knowledgefactoryco.com. Please email resume to Dr. Aldo Leopardi at aldo@aldoleopardi.com.

Georgia (Gwinnett) - Seeking Associate Prosthodontist with Partnership Opportunity: A fast growing Prosthodontic Practice in the Heart of Gwinnett is looking for a qualified Prosthodontist to join our team. Candidate must possess excellent clinical skills; Good bedside manners; Ability to grow professionally; Must be experienced and possess a skill in developing a practice. Benefits Available. Competitive Salary. Partnership Opportunity. Email: castrodds@gmail.com

Illinois (Chicago) - Established prosthodontic practice, beautiful location, seeks prosthodontist for partnership leading to ownership. Excellent opportunity to become established in downtown Chicago. Suitable for transition from academia, recent graduate from specialty training program, or experienced practitioner. All replies confidential. Reply to prosthodds1@gmail.com.

Illinois (Northwest Suburbs) - Prosthodontist P/T position; M/W: Prosthodontic office in the Northwest suburbs of Chicago seeking a qualified prosthodontist. Please email: dentalpracticedds1@gmail.com.

Illinois (University of Illinois at Chicago) - SEARCH EXTENDED: Clinical Assistant/ Associate Professor

The Department of Restorative Dentistry at the University of Illinois at Chicago under the leadership of Stephen Campbell, DDS, MMSc, seeks applicants for two full-time non-tenure Clinical Assistant/Associate Professor level positions.

Responsibilities include preclinical and clinical instruction in all aspects of the restorative sciences. Qualifications include a Doctor of Dental Surgery (DDS)/Doctor of Dental Medicine (DMD) or its equivalent. Prior teaching experience and advanced clinical training is desirable, but not required (board eligibility/certification is desirable where appropriate). Currently hold or be eligible for dental licenses in Illinois and a strong commitment to interdisciplinary care and willingness to engage other academic departments.

Preferred qualifications include Diplomate status in the American Board of Prosthodontics, demonstrated experience in teaching, mentoring, research, and service, demonstrated ability to mentor students, experience with peer-reviewed publishing, strong interpersonal skills and demonstrated experience in fostering collaborative relationship between disciplines.

For fullest consideration please apply by October 1, 2016 at <https://jobs.uic.edu/job-board/job-details?jobID=65103> and include a cover letter, curriculum vitae, and the names and contact information of three references. Salary and academic rank commensurate with experience and qualifications.

This position will begin December 1, 2016.

The University of Illinois at Chicago is an Equal Opportunity, Affirmative Action employer. Minorities, women, veterans and individuals with disabilities are encouraged to apply. The University of Illinois may conduct background checks on all job candidates upon acceptance of a contingent offer. Background checks will be performed in compliance with the Fair Credit Reporting Act.

Massachusetts (Boston) - A terrific opportunity for the right person to join a well established and well respected 25 year practice limited to fixed, removable, and implant services. Three world class dental schools nearby for anyone interested in teaching opportunities. Eventual ownership possible for the right person. Send resume to: louisrissin@gmail.com.

New York (Rochester) - Established Prosthodontic/Implant Practice looking for a highly skilled associate. A rare opportunity for a skilled Prosthodontist with strong communication skills to join a very busy practice focusing on complex dental issues and specializes in full-arch restorations, called Hybridge. Mentoring by the founder of Hybridge Implants. Teaching opportunities available. Send resume to: FLaMar@Hybridgeimplants.com

New York (Stony Brook University, School of Dental Medicine) - Stony Brook University School of Dental Medicine invites applications for a full-time, tenure or non-tenure track position at the Clinical Assistant/ Associate or Assistant/Associate Professor level in the Department of Prosthodontics and Digital Technology.

The selected candidate will serve as Director of Predoctoral Education in Prosthodontics and will be involved in the Department's clinical, academic, research and administrative activities at both the predoctoral and postdoctoral levels. Candidates should demonstrate clear potential for academic growth in teaching, clinical practice and research, and possess excellent communication, organizational and interpersonal skills.

A DDS/DMD degree from a CODA accredited dental school or equivalent foreign degree is required. The successful candidate must have qualifications sufficient for dental licensure in New York State. A clinical certificate in Prosthodontics from a CODA-accredited postdoctoral program is also required. The applicant must have passed Section A of the American Board of Prosthodontics (ABP) certification examination and currently be board eligible. Preferred qualifications include board certification from the American Board of Prosthodontics (ABP), advanced degree(s) (Ph.D., MS or similar) and previous clinical and teaching experiences.

Applications will be accepted until the position is filled. Those interested in this position should submit a State Employment Application, a letter of interest, statement of career plans, curriculum vitae, and the names and contact information of three academic references to: Elizabeth A. Schroeder, Senior Staff Assistant School of Dental Medicine Department of Prosthodontics and Digital Technology Westchester Hall, Room 1105 Stony Brook University Stony Brook, NY 11794-8712

For a full position description, or to apply online, visit: www.stonybrook.edu/jobs (Ref. # F-9696-16-10). AA/EOE. Female/Minority/Disabled/Veteran

Pennsylvania (University of Pittsburgh) - The University of Pittsburgh School of Dental Medicine is seeking applications for the position of full-time Assistant Professor in the Department of Prosthodontics. The position is in the non-tenure-stream. Responsibilities include didactic as well as pre-clinical and clinical teaching in Fixed and Removable Prosthodontics at the pre-doctoral. Participation in the University Dental Health Service is optional. Requirements for this position are: Applicants must have a DDS or DMD degree and a Certificate in Prosthodontics from an ADA accredited school. They must also be eligible for a PA dental license. Diplomates of the American Board of Prosthodontics are preferred. The Department of Prosthodontics is responsible for the disciplines of Fixed and Removable Prosthodontics, Occlusion, Dental Materials and Digital Dentistry. Application reviews will begin immediately and will continue until the position is filled. The School of Dental Medicine is centrally located on the main campus of the University of Pittsburgh which is recognized as an international center of learning and research. The University of Pittsburgh is an Affirmative Action, Equal Opportunity Employer and values equality of opportunity, human dignity and diversity. The campus is just minutes from corporate and cultural downtown Pittsburgh. Salary for this position is commensurate with experience and qualifications. Please send curriculum vitae and the names and addresses of three references to:

Dr. Louis Jannetto
University of Pittsburgh
School of Dental Medicine
Department of Prosthodontics
3501 Terrace Street, Room 2025,
Pittsburgh, PA 15261
Tel: (412)648-8840 E-Mail: lbjl@pitt.edu
EEO/AA/M/F/Vets/Disabled

Texas (Texas A&M University) - Texas A&M University College of Dentistry is seeking applicants for a full time position as Director of the three year Advanced Specialty Education Program in Prosthodontics in the Department of Restorative Sciences. This is a non-tenure or tenure track position at the rank of

associate professor or professor, with salary and rank commensurate with qualifications/experience. Applicants must possess a DDS/DMD degree or equivalent, board certification status with the American Board of Prosthodontics, a record of publications and scholarship as well as administrative/budget experience. Prior practice experience and teaching is highly desirable, and the applicant must be eligible for licensure in the State of Texas. Responsibilities include full program oversight, to include course management and curriculum development commensurate with the accreditation standards of the Commission on Dental Accreditation, as well as clinical and didactic resident instruction, and supervision of research. The position will be available June 1, 2017. The opportunity for extramural private practice is also available. Review of applications will begin immediately and continue until the position is filled. Applicants should provide a letter of interest indicating date of availability, curriculum vitae, a statement of teaching and research and contact information for three references to Dr. Steve Karbowski (skarbowski@bcd.tamhsc.edu).

EEO/AA Statement: Texas A&M University College of Dentistry is an Equal Opportunity/Affirmative action/Veterans/Disability employer, committed to excellence through diversity.

Washington D.C. - Opportunity Knocks But Once: We are looking for a motivated, personable individual to join our prosthodontic practice with a path to ownership in the future. The practice is positioned in two separate highly sought after locations in the West End section of Washington, D.C. and in McLean, Virginia. It's a modern, state of the art Prosthodontic Practice with a 35+ year history. We are fully digital and paperless; CBCT, implant surgery, in-house lab with 3shape scanner and ceramist with 30 years of experience. All aspects of Prosthodontic therapy are active therapeutic features of this practice. We are a fee-for-service practice and our receivables are negligible. We are linked to multiple high level study clubs and have an outstanding position within the local community. Excellent compensation, 401K, health benefits and great working environment. Interested candidates can send their CV letter/resume via email (doctors@smilesinternational.com) to set up a phone interview.

Wisconsin (Madison) - Prosthodontic practice established 20+ years ago in beautiful city seeks Associate or Partner with opportunity for ownership. Suitable for transition from Academia, recent specialty graduate or experienced practitioner. With the highest level of integrity we provide compassionate and professional care, striving to exceed the expectations of our patients. 4 day work week, 3 days of hygiene. Consistently growing and exceeding \$1M+ in annual collections. Digital. Cerec technology. Complete with on-site lab, highly trained lab technician, exceptional doctor/owner and a stellar staff! Voted top 10 places to live in US. Please contact: krysta.pom@gmail.com

Wisconsin (Waukesha) - Prosthodontist Job Opening in Wisconsin. Job Description: Perform all phases of prosthetic dentistry and related dental implant services to the appropriate standards as set forth by the practice. Ability to build good rapport with patients and staff and promote the success of the center. Be willing to take a leadership role in the center with an emphasis on driving center profitability. Possess a patient-centered mindset and approach to treatment planning and day to day center operations. Job Requirements: Professional Degree: DDS/DMD; Certificate in Prosthodontics from an American Dental Association accredited program; Licensed in Wisconsin. Salary and Benefits: Competitive salary and bonus based on production. Contact megan.rades@eonclinics.com.

Practices for Sale

California (Napa) - Prosthodontic practice est in 1985 occupies 1712 sq ft with 4 fully equipped operatories, 3D CBCT and removable prosthetics lab. Collections just under 1 million on a 3 day work week with 2 days of hygiene per week. Contact Tim Giroux at 530-218-8968 or wps@succeed.net.

California (Northern California) - Northern California Practice Sales currently has current prosthodontic opportunities available in San Jose, San Francisco, and Napa. For more information, please send a cover letter and current CV to molinelli@aol.com or call 650-347-5346.

California (Sacramento) – Prosthodontics Practice and Building for Sale: Practice established 36 years ago. Well respected practice has production of approximately \$600,000 for last 5 years. Three patient days a week with no hygiene. Many patients would like it if hygiene was added to practice. Seller will help transition patients and if buyer would like would consider working as your associate. Building is single story Tudor style in a well maintained predominately dental complex and is 3000 square feet. Practice is approximately 1600 square feet with 3 operatories and a large well equipped lab. Remaining space income property or room to expand. E-MAIL prosthodontics01@gmail.com

Georgia (Atlanta) – Atlanta Area Prosthetic Dental Practice: Thriving prosthetic dentistry practice in busy Publix Shopping complex, 1625 sq ft. 2 operatories w/ plumbed space for 2 additional. Over \$430k in revenue with strong cash flow. Established referral network over 20 yrs. Great 2nd office or new practice opportunity. Email lynn@5thaavc.com for more information.

Indiana – Midwest prosthodontics opportunity! This practice, established in 1980 is located in a large midwest metropolitan area between Chicago, Indianapolis & Toledo. The beautiful 2,700 sq. ft. stand alone office has 4 treatment rooms and great street visibility. The practice does fixed, removable, implant prosthodontics and maxillofacial prosthetics and has a gifted lab technician and full lab onsite. This is a FFS practice with a great referral base and staff. Annual revenues are \$900K on a comfortable 4 day work week with 6 weeks of vacation. Seller is looking to retire but will assist the purchaser with introductions and the transition. For inquiries call 260-602-9226 or email hoosierdeb@frontier.com.

Maryland (NW Maryland/DC Area) – FOR SALE: a well-established, cosmetic and restorative dental practice with a significant prosthodontic component. 2016 income should be approx \$1.1M. Office is 2900 SF; there are 6 fully equipped ops, 2 of which are used for hygiene. Email transitions@mcgillhillgroup.com.

Massachusetts (Andover) – Boston Area Prosthodontic Practice Leading to Ownership. Board eligible/board-certified prosthodontist position available for my 25 year old well-established and well-respected prosthetic practice leading to ownership within 6 months to 1 year. Three world class dental schools in the area for someone also interested in teaching opportunities. \$400,000-\$500,000/year on 2 days per week. Contact louis.rissin@gmail.com or 978-686-2620.

Midwest – Own a thriving Prosthodontic practice. This practice collects over \$1,125,000/year with single doctor. Lab, digital, dozens of strong referrers, Levin trained, well managed, patient focused and very large growth potential! With a service area of approximately 340,000, this city takes pride in a super strong university paired with a medical, tech, government and housing economy virtually unaffected by the 2008 crash. Always ranked top 10 in U.S. places to live. Please contact prosthoffice16@gmail.com.

Nevada (Las Vegas) – Las Vegas Prosthodontic practice cash flows better than most with 2015 collections exceeding \$1M. Fantastic building in highly desirable neighborhood with unprecedented curb appeal, giving your patients the feel of a luxury spa or weekend getaway. 2,100 sf w/ 4 fully equipped ops. \$770K excluding ARs. Call Tim 800-641-4179.

New York (Syracuse) – Syracuse Prosthodontic and Implant Practice Leading to Ownership. Thriving 32 year old Prosthodontic practice looking for qualified candidate to buy in 6 months to 1 year. Gross revenues \$1.2 million on 25 hours per week with low overhead. Totally fee for service with 3 days of hygiene and long term staff. Office is 2000 square feet with 4 fully equipped ops all with digital xray, Plan Meca CBVT which also does Panorals and Pan Bitewings, T-scan, TruDenta diagnostics, Digital camera, Intraoral cameras in ops, latest CEREC Acquisition unit and MCXL Milling unit, Piezosurgery, fully computerized office located in medical and hospital district. Lab is good size and fully equipped. Currently placing about 70 implants per year (mostly Nobel Active CC) and restoring many more (Nobel Active, Straumann, 3i Certain, Implant Direct). The beautiful Finger Lakes are nearby with the opportunity to live on


the water and commute to work easily. We are surrounded by wineries, great hospitals with easy access to medical care, several major universities, medical school, VA hospital, and a vibrant downtown. The university has competitive Division I football and basketball programs and there is minor league Hockey and Baseball. The community supports museums, concert venues, theater, symphony, and festivals. It is a great place to raise a family with affordable housing. Please send resume and cover letter to jbsprotho@gmail.com or call 315-447-3145.

Texas (Austin) – Established, profitable, high percentage net practice is available for buy in or buy out. The practice is primarily oriented in implant dentistry, fixed, and removable prosthodontics. 5 fully equipped operatories, 3D CBCT and fully equipped lab. In case of buy out owner will stay on part-time as needed to facilitate the transition. Contact austindentist5@yahoo.com.

Texas (Pearland) – Practice was established as satellite office of Houston Dental Implant Center in 2006. Great community 16 miles away from Houston. PPO and fee for service. 3 ops, 1 pano, Digital x-ray. Average collection per year \$500,000 on 4 days; not on full potential. Practice focus on Prosthetics and Implants. Suite is about 1,600 sq/ft and is for sale as well. Please email docrmero@me.com for more information.

Utah (Salt Lake City) – Practice and office space for immediate purchase and transition. Primarily oriented in implant, fixed, and removable prosthodontics. 30 year established practice with good referral sources. 3 ops with room for expansion. 1755 sq. ft. Great opportunity and very reasonably priced at \$300,000, which includes the condominium building and all equipment. Currently grossing \$300K+ on 2-2.5 days a week. Potential for more on 4 days a week. Contact at: 801-450-8057. Send CV or resume to Linda Montgomery at leefamily@utahisp.com. Would like to retire as soon as possible.

**ASTRA TECH
IMPLANT SYSTEM**



OUR WORLD IS NOT FLAT

DENTSPLY Implants does not waive any right to its trademarks by not using the symbols ® or ™. 32671114-USX1605 © 2016 DENTSPLY. All rights reserved.



NEITHER IS THE ANATOMY OF YOUR IMPLANT PATIENTS

Your world is already full of clinical challenges so why work harder because of conventional thinking? Instead of augmenting sloped ridges to accommodate flat-top implants, it's time to discover a simpler solution by using an implant that follows the bone. Because sloped-ridge situations call for anatomically designed sloped implants.

OsseoSpeed™ Profile EV

It's time to challenge conventional thinking

Follow DENTSPLY Implants



www.dentsplyimplants.com



INTRODUCING

Variolink[®] Esthetic

Adhesive Cement System

**“Esthetic Cementation
made Simple!”**

*The adhesive cement for exceptional
esthetics and user-friendly application...*

- Exceptional handling and easy clean-up
- Amine-free for long-term shade stability
- Reliable bond strength results with a universal, easy to use bonding system



Try Variolink Esthetic today for **FREE!**
Visit www.ivoclarvivadent.us/variolink

ivoclarvivadent.com

Call us toll free at 1-800-533-6825 in the U.S., 1-800-263-8182 in Canada.
© 2016 Ivoclar Vivadent, Inc. Ivoclar Vivadent, Variolink and IPS e.max are registered trademarks of Ivoclar Vivadent, Inc.

**ivoclar
vivadent**[®]
passion vision innovation